

Swiss neurological eponyms

■ C. L. Bassetti

Department of Neurology, University Hospital of Zurich

Introduction

The birth of modern neurology in the 19th century was characterised by the predominance of the clinical method, which consisted in the recognition of symptoms and signs and the study of their correlation with anatomic-pathological findings [1]. This approach was accompanied by the widespread use of eponyms. Until today more than 450 neurological eponyms have been reported, similarly distributed between signs, reflexes, phenomena and syndromes [2].

The value of eponyms has become controversial in modern medicine. For some authors eponyms allow the maintenance of “a self-perpetuating Hall of Fame” while blocking “clear thinking and expression” [2]. Their value is challenged by the existence of redundant eponyms for similar phenomena and similar eponyms for diverse phenomena as well as by unclear definitions. According to Steigler’s law eponyms also rarely honour the first describer [3]. On the other hand, the same discovery can be made subsequently by others who may claim priority. Similar (or even same) reflexes, for example, have been rediscovered and renamed over decades [4, 5]. To other authors eponyms are justified because they provide a short label for a complex list of medical terms, preventing the use of unpractical scientific eponyms [6]. Furthermore, eponyms represent a link with the roots of medical history and the scientists who contributed to its progress.

The aim of this paper is to give an overview of *clinical* neurological eponyms that have been attached to Swiss neuroscientists¹. Some of these eponyms are still used today, others have not survived the challenge of time. Most of them are, however, attached to the history of the Swiss Neuro-

logical Society, for the centenary of which this special issue of the *Swiss Archives of Neurology and Psychiatry* is dedicated.

Signs and reflexes

Bing’s sign (paradoxe Fussgelenk-Reflex)

In 1918 Bing reported a pathological reflex in spasticity consisting of a plantar flexion of the foot following a single percussion of the dorsum of the foot at any point over the line connecting the medial with the lateral malleolus [8]. This reflex was observed by Bing in 14 out of 19 patients with organic spasticity, whereas a Babinski’s sign was found only in 10 patients. This sign, to which Bing himself referred to as “Bingscher Reflex” in his textbook [9], is still used in different countries including the Czech Republic (Prof. Karel Sonka, personal communication). Wartenberg in his book on reflexes questioned the usefulness of Bing’s observation [4]. Lenggenhager and von Monakow also described pyramidal signs as alternatives to the Babinski’s sign (see below).

Robert Bing (1878–1956), born in Strassburg (at that time still belonging to Germany), studied and lived in Basel. He trained in neurology with Dejerine and Babinski in Paris and in neurosurgery with Horsley in London. He was one of the founders of the Swiss Neurological Society (SNG, 1908), of which he also became the 4th president (1919–1922). In 1907 he started an outpatients’ clinic in Basel, where he later became professor (1932). According to Minkowski it was Bing who convinced von Monakow and Dubois to found the SNG [10].

¹ Neuroanatomical, -physiological and other nonclinical eponyms named after Swiss neuroscientists (Aeby, Burgdorfer, Forel, Goll, Kölliker, von Monakow, Valentin) as well as clinical eponyms of non-Swiss neuroscientists who worked in Switzerland (Cushing, Lichtheim, Quincke, Rosenthal, Schiff, etc.) will not be discussed (we refer to other sources for this [7]). Only a few neuropaediatric syndromes named after Swiss paediatricians have been listed.

Correspondence:

Claudio L. Bassetti, MD
Department of Neurology
University Hospital
Frauenklinikstrasse 26
CH-8091 Zurich
e-mail: claudio.bassetti@usz.ch

Bing was an excellent clinician and wrote (first edition in 1909) one of the first neurological textbooks in German, which was translated into six languages and also in the USA became a standard book. He also published on spinocerebellar tracts and history of neurology.

Lenggenhager's sign

Lenggenhager described a new pyramidal sign in 1945. Firm stroking of the foot from the lateral to the medial part of the distal sole (at the base of the toes) was reported to elicit a dorsiflexion of the toe in the presence of pyramidal lesions (fig. 1). The reflex was suggested to be more sensitive than the Babinski's sign (e.g. in the course of spinal cord compression) and to be present only if the sensation of the foot is intact. Others have found this response also in healthy subjects [11].

Figure 1 Lenggenhager's sign (Fussballen-Streichreflex). Stroking of the foot from the lateral to the medial part of the distal sole (at the base of the toes), (modified from Lenggenhager, *Schweiz Med Wochenschr.* 1945;32:693–4).

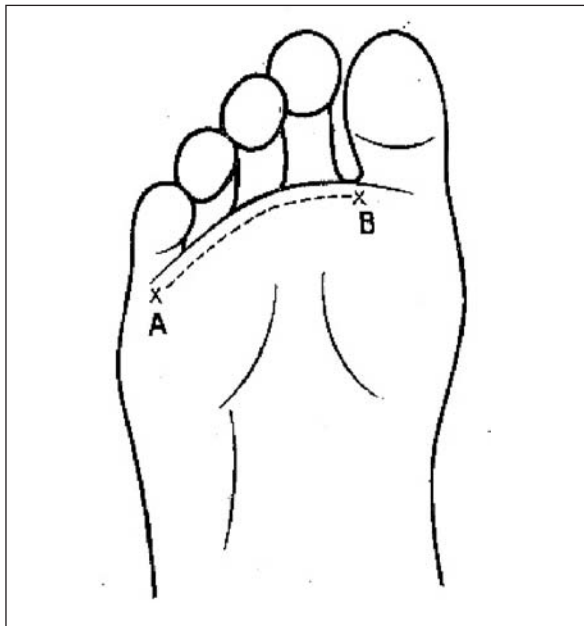


Figure 2 Lüthy's sign (Flaschentest zur Erkennung der Medianuslähmung), from the original publication in 1962 [12].



Karl Lenggenhager (1903–1989), born in Chur, trained with De Quervain in Berne and later became his successor as chair of the surgery department of the university hospital in Berne (1942–1971).

Lüthy's sign (Flaschentest, -zeichen)

Lüthy's bottle sign refers to a weakness of thumb adduction (m. adductor pollicis), opposition and flexion due to a median nerve lesion [12]. When the patient grasps a large bottle (in case of women or children Lüthy suggested to use a glass), a gap appears between the object and the skin web between the first and second finger because of a weakness of the m. abductor pollicis brevis and m. opponens pollicis (fig. 2). In addition, as pointed out by Lüthy in his original description, the bottle cannot be held because of weakness of the m. opponens and m. flexor pollicis brevis. It is said that Lüthy was always keeping an (empty) bottle of Champagne in his office to test for this sign.

Fritz Lüthy (1895–1988), born in Solothurn, trained in neurology with Minkowski in Zurich, with Nonne and Jakob in Hamburg and with Greenfield in London. He became Minkowski's successor as chair of the Neurology department at the University Hospital in Zurich (1955–1967) where he started the first Swiss headache outpatient clinics and created an EEG² and an EMG division. He became the 15th president of the Swiss Neurological Society (1950–1953).

Lüthy's contributions were mainly on neuropathological topics and particularly on extrapyramidal disorders (his habilitation 1931 was on Wilson's disease). He was also among the first to recognise the presence of sensory disturbances in patients with amyotrophic lateral sclerosis.

Magistris-Roth's sign

The contraction of skeletal muscle upon direct percussion was first described by Schiff (1858), then Babinski and Jarkowski (1911) have emphasised that this response ("idiomuscular response") is reduced or abolished in myopathies [13]. Magistris and Kohler, inspired by preliminary observations made by their colleague Roth in Geneva, reported an increase of this muscle response to percussion in patients with peripheral conduction block and a decrease of the response in patients with peripheral axonal lesions (fig. 3).

² An EEG division already existed at the University Hospital in the Neurosurgery department.

Michel Roland Magistris (1945), of Swiss and French nationality, trained in neurology in Geneva, Paris and Montreal. Since 1989 he has been the head of the ENMG and neuromuscular disorders unit of the Clinical Neurosciences department of the University Hospital in Geneva. Magistris works on clinical and neurophysiological topics related to neuromuscular disorders.

Figure 3 Magistris-Roth's sign: response of paralysed muscle in patients with conduction block (n = 47), mixed lesions (n = 19) and axonal lesions (n = 53). Modified from Magistris et al., *Neurology*. 1996;47:1243–6 [13].

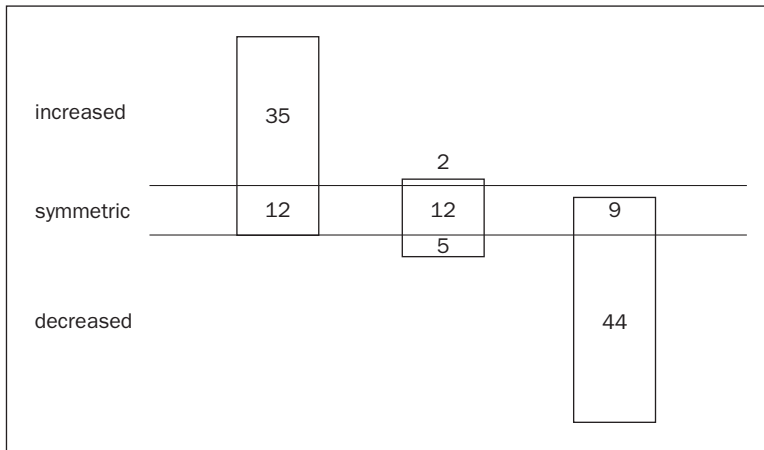
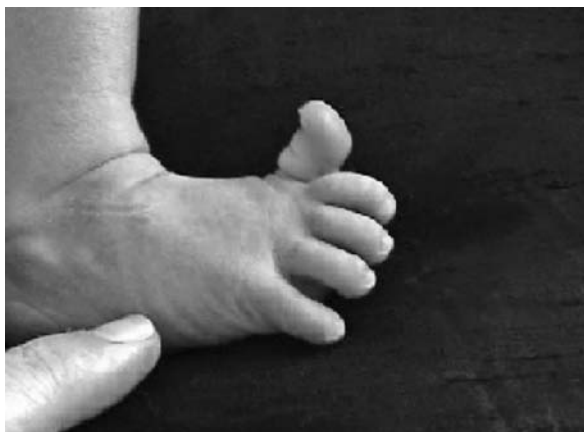
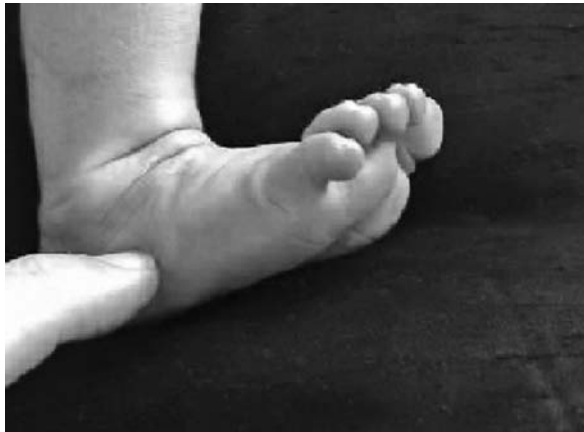
Figure 4 Von Monakow's sign (äusserer/lateraler Fussrandreflex, 1909) and Babinski's sign elicited in a healthy 1-month-old newborn.



Von Monakow's sign

In 1909 von Monakow described as pyramidal sign the slow abduction of the foot, with and without dorsiflexion of the toe, following gentle stroking of the lateral foot sole from the bottom to the top (fig. 4) [14, 15].

Constantin von Monakow (1853–1930), the “father” of Swiss Neurology, was born in Russia and arrived in Switzerland in 1866. In 1887 he started the first neurological outpatient clinics and seven years later in Zurich he was appointed to the first chair of neurology of the country with the title of extraordinary professor. He was the first president of the Swiss Neurological Society (1909) and the first chief editor of the *Swiss Archives of Neurology and Psychiatry* (1917) [16].

Von Monakow was one of the leading neuro-anatomists and neuropsychiatrists at the turn of the 20th century. Among his most lasting contributions are those on the theory of brain localisation and on diaschisis (see below). A contribution of Jagella and Krestel in this “Festschrift” discusses von Monakow's life and oeuvre in more detail.

Prévost's sign (law)

The “deviation conjuguée” of the head toward the diseased hemisphere is called after Prévost.

Jean Louis Prévost II (1838–1927), born in Geneva, received neurological and neuropathological training with Vulpian (Paris). Dejerine and Paul Dubois (1848–1918), the 2nd president of the Swiss Neurological Society (1910–1916) and a pioneer in psychotherapy, were his pupils. Prévost became professor of physiology in Geneva (1897–1913) where he also worked on neuroregeneration processes. He founded the *Revue médicale de la Suisse Romande*.

Veraguth's fold

Veraguth reported as a sign of depression the observation of a skin fold that runs obliquely from the upper inside to the lower outside of the upper eyelid.

Otto Veraguth (1870–1944), born in Thusis, trained in neurology with von Monakow in Zurich. He later, as a private practitioner in neurology, became the 5th president of the Swiss Neurological Society (1922–1924). Veraguth worked on clinical and pathological topics, including the psychogalvanic reflex [10].

Phenomena

Landolt's forced normalisation

In 1953 Landolt described the appearance of psychiatric disturbances in patients normalising their EEG and becoming seizure free after antiepileptic treatment, a phenomenon that after him was named "forced normalisation" [17]. The association between psychiatric disturbances and seizure freedom had already been described before him by several authors including Griesinger (epileptoid state, 1860), who had been the Director of the Zurich psychiatric hospital ("mental asylum") before he was offered the chair of neurology in Berlin [18]. Landolt's rediscovery of the complex link between psychiatric disturbances (including psychoses) and epilepsy triggered research and discussions that have kept their relevance until today.

Hans Heinrich Landolt (1917–1971), born in Strasburg (at that time still belonging to Germany), studied in Zurich (among others with Bleuler) and Paris (with Garcin). In 1955 he was appointed director of Swiss Epilepsy Centre in Zurich.

In Switzerland Landolt was with Ruedi Hess at the University Hospital in Zurich a pioneer in the use of the EEG in the late 1940s and is as well remembered scientifically because of his publications on epileptic syncope ("temporale Ohnmacht", [19]). He was also involved in testing and using new antiepileptic drugs.

Von Monakow's diaschisis

This refers to a functional disturbance, limited in space and time, of healthy brain areas distant from a focal cortical brain lesion. Von Monakow described this phenomenon in his monographs "Gehirnpathologie" (1905) and "Lokalisation im Grosshirn und der Abbau der Funktion durch kortikale Herde" (1914) [20, 21]. Von Monakow's ideas on diaschisis influenced the work of many authors including those of Bleuler, W. R. Hess, Sherrington, Head, Macdonald Critchley, Luria and Teuber [22]. Clinical, EEG and neuroimaging observations have confirmed and expanded von Monakow's original observations and concepts on diaschisis [22–24].

Syndromes and diseases

Bärtschi-Rochaix' syndrome

This eponym refers to a syndrome of migrainous headaches ("migraine cervicale") with ipsilateral numbness and coldness of the arm, visual scotomas and vertigo secondary to degenerative changes of the cervical vertebral column [28].

Werner Bärtschi-Rochaix (1911–1994) was the first director of the EEG division at the University Hospital in Berne (1953–1956). He founded the first society of clinical neurophysiologists in Switzerland (1948, "Schweizerische Arbeitsgemeinschaft für Elektroencephalographie"). In 1956 he became the chair of neurology at the University Hospital in Cairo. Bärtschi-Rochaix served as 19th president of the Swiss Neurological Society (1964–1967).

Bing's headache (Bing-Horton's syndrome)

Bing described in his neurology textbook (starting in the 1913's edition of the "Lehrbuch der Nervenkrankheiten") cluster headache as "erythroproso-palgia" (erythros = red, prosopon = face) in analogy to the erythromelalgia of Weir Mitchell [25]. This description, although initially incomplete, impressed Bayard T. Horton who adopted Bing's interpretation. The first description of cluster headache is probably that in 1745 by Gerardi van Swieten [26]. In the English literature the first descriptions of the syndrome are associated with the names of Harris (1926) and Horton (1939) [27], although Bing's oeuvre had rapidly been translated into English by Haymaker.

Binswanger's disease

In 1894 Binswanger described in eight patients a new form of slowly progressive dementia punctuated by apoplectiform focal attacks associated with selective white-matter atrophy (patchy or diffuse) and ventricular dilation [29]. He named the disorder "encephalitis subcortical chronica progressiva". Alzheimer named the disorder after Binswanger in 1902 [30]. Olszewski suggested 1962 the term "subcortical arteriosclerotic encephalopathy Binswanger's type". The specificity of this syndrome has been questioned [31].

Otto Ludwig Binswanger (1852–1929, fig. 5), born in Münsterlingen, had trained in neuropathology with Meynert (Vienna) and in neuropsychiatry with Westphal (Berlin). He was the chair

Figure 5



Otto Ludwig Binswanger
(1852–1929).

Figure 6



Gustave Roussy
(1874–1948).

of the mental asylum Psychiatry in Jena (1882–1919), where he had as co-workers Vogt, Brodmann and Berger.

Binswanger was one of the most famous neuropsychiatrists of his time. He was the physician of Nietzsche. Binswanger published on epilepsy, neurasthenia, hysteria, neuropathology of syphilis and general psychiatry.

Bonnet's syndrome

This eponym refers to the appearance of visual hallucinations in elderly patients with impaired vision, typically in isolation and with preserved insight [32]. The eponym was coined by de Morsier (see below) [33]. The hallucinations typically occur in the evening. Eye closure, gaze shifts or the attempt to touch them may lead to disappearance of hallucinations or to changes in their size or character. The pathogenesis of these hallucinations is considered to be a deafferentation of visual areas.

Charles Bonnet (1720–1793), born in Geneva, was a philosopher and natural scientist and became professor of Zoology and Botany in Geneva. He described the visual phenomena experienced by his grandfather after cataract surgery. He wrote on

entomology, photosynthesis and parthenogenesis and became famous because of his regeneration experiments. A progressive visual problem forced him to focus on theoretical topics and philosophy.

Dejerine-Roussy's syndrome

In 1906 Dejerine and Roussy described the clinical pentade (persistent hemihypaesthesia, pain, mild hemiataxia, hemichoreoathetosis and mild hemiparesis) of lateral thalamic strokes [34]. This observation confirmed the role of the thalamus as "carrefour sensitif", a concept long opposed by Charcot [35, 36].

Joseph Jules Dejerine (1849–1917) was born in Alsace (France) and studied in Geneva before becoming a pupil of Vulpian in Paris [37]. He was a close friend of von Monakow and Paul Dubois and the teacher of André-Thomas (1867–1963) and Oskar Vogt. His wife was Augusta Klumpke (1859–1927), who was the first female intern admitted as "interne des hôpitaux" [38].

Gustave Roussy (1874–1948, fig. 6), born in Vevey, studied in Geneva and was then a pupil of Dejerine in Paris, where he subsequently obtained the chair of anatomo-pathology (1926) and became rector of the Sorbonne (1937) and member of the Academy of Sciences. His late life (terminated by suicide) was shadowed by persecutions by the Vichy government and financial scandals. He was rehabilitated posthumously and the world-famous cancer centre in Villejuif, which he had founded in 1934, was named after him (Institute Gustave Roussy).

Gustave Roussy made several clinical and pathological contributions to neurology and cancerology including the description of the lateral thalamic syndrome (with Dejerine), cortical sensory loss (with Foix) and polyneuropathy with tremor (with Lévy, see below).

De Morsier's syndromes I and II

De Morsier syndrome I refers to a variety of behavioural, psychomotor and sensory disturbances appearing in the course of diencephalic disorders. De Morsier's syndrome II refers to the triad dwarfism, nystagmus and micropupils.

Georges de Morsier (1894–1982), born in Paris, trained in Geneva with Maurice Roch, Paul-Louis Ladame (1842–1919), the 3rd president of the Swiss Neurological Society, SNG), and Edouard Long (1868–1929), a pupil of Dejerine who was given the first chair of neurology at the University Hospital

Figure 7



Johann Friedrich Horner (1831–1886).

in Geneva in 1919 (with the title of extraordinary professor of neuropathology), however, without any department and beds, and became the 7th president of the SNG (1927–1930). De Morsier succeeded Long as chair of neurology in Geneva (1940–1962), where in 1953 neurology was separated from the department of medicine and became independent. De Morsier became the 13th president of the SNG (1946–1949) [39].

De Morsier worked on diencephalic syndromes, head trauma and encephalitis. He also confirmed the existence of Kallmann's syndrome (olfactogenital dysplasia) [40] and coined the eponym "Charles Bonnet's syndrome" [33].

Fanconi-Turler's syndrome (familial ataxic diplegia)

In 1951 Fanconi and Turler first described a syndrome characterised by cerebellar ataxia, spastic pareses, supranuclear eye movement disorders (and nystagmus) and mental retardation [41]. This syndrome is unspecific and only rarely used today.

Guido Fanconi (1892–1979), born in Poschiavo, chaired the Children's Hospital in Zurich (1929–1962) and served as president of the International Paediatric Association (1947–1950). His name is attached to more than 15 conditions.

Glanzmann-Saland's syndrome

In 1935 Glanzmann and Saland reported the occurrence of severe polyneuropathy following diphtheria [42]. The term, today almost forgotten, has erroneously also been used as synonym for the Guillan-Barré syndrome.

Eduard Glanzmann (1887–1959), born in Lucerne, trained in paediatrics in Berlin and Berne, where he became chair of the University Children's Hospital (1932–1957) and dean (1943–1945). His name is linked with several paediatric eponyms.

Horner's syndrome

In 1869 Horner described the symptom triad (ptosis, miosis, enophthalmos) which was afterwards named after him [43]. Although the triad had been observed in patients (Pourfour du Petit, 1727; Budge and Waller, 1851) and experimentally (Claude Bernard, 1852) before him, Horner had the merit to attribute the clinical triad to a lesion of cervical sympathetic nerve.

Johann Friedrich Horner (1831–1886, fig. 7), born in Zurich, is considered the founder of Swiss Ophthalmology. He trained with von Graefe in Berlin and in 1862 in Zurich was appointed to the first chair of Ophthalmology in Switzerland, despite the strong opposition of Theodor Billrot [3]. He was pivotal in the foundation of the Burghölzli Psychiatric Clinic and the Zurich Cantonal Medical Association.

Horner was a gifted clinician and surgeon (cataract, glaucoma) and, in addition to the description of the symptom complex named after him, he introduced antisepsis in eye surgery and made descriptions of herpes infection of the cornea and colour blindness [44]. J. F. Horner made excuse of his limited scientific oeuvre by observing that prolific writers are bad clinicians [3].

Joubert-Boltshauser's syndrome

This eponym refers to a rare autosomal recessive syndrome (genetically heterogeneous) with episodic hyperpnoea and jerky eye movements in the newborn, followed by mental retardation and cerebellar ataxia. The neuroimaging hallmark is a subtotal vermis agenesis and the so-called molar tooth sign at the pontomesencephalic junction [45]. The syndrome was reported by Joubert in 1968 and confirmed by Boltshauser and Isler in 1977 [46].

Eugen Boltshauser (1945) is chair of neuropaediatrics at the University Children's Hospital in Zurich (since 1988). He has published on several neuropaediatric topics and particularly on cerebellar malformations and disruptions.

Kaeser's syndrome

(Kaeser's scapulo-peroneal myopathy)

In 1964/65 Kaeser described an autosomal dominant form of scapulo-peroneal atrophy (fig. 8) which he thought to be neurogenic in origin (spinal muscle atrophy) [47, 48]. Recent studies have demonstrated a myopathic origin of the disorder related to desmin mutations [49]. Autosomal and

x-linked forms have been reported. Before Kaeser Brossard (1886) and Davidenkov (1928) had described similar scapulo-peroneal forms of muscle atrophy which have now, however, been linked to other genetic deficits [49].

Heinrich Kaeser (1924–2006), born in Basel, trained with Lambert at the Mayo Clinic and served as chair of neurology (1965–1992) – the 3rd after Bing (1932–1948) and Georgi (1948–1965) in the history of the University Hospital in Basel. He was the 29th president of the Swiss Neurological Society (1985–1987) and Chief editor of the journal “European Neurology” (1968–1992).

Kaeser published on several clinical topics but mainly on disorders of the peripheral nervous system and on electromyography.

Lutz's syndrome
(posterior internuclear ophthalmoplegia
Bielschowsky-Lutz, INO of abduction)

Lesions of the medial longitudinal fasciculus (MLF) manifest with (anterior) internuclear oph-

Figure 8 Muscle weakness (black: severe, grey: mild) in Kaeser's syndrome (from Kaeser, Brain. 1965;88:407–18 [47]).

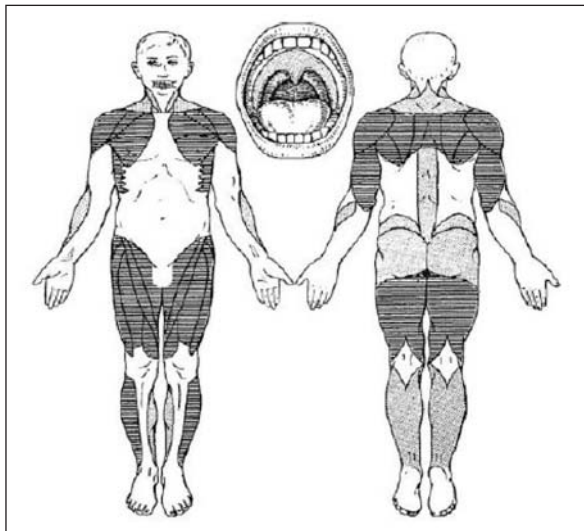
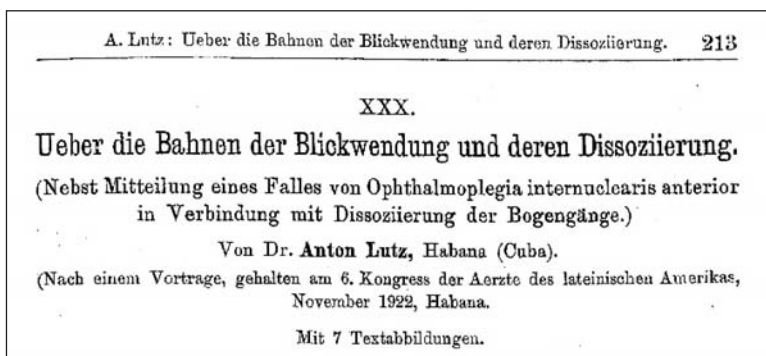


Figure 9 First report on posterior interior ophthalmoplegia by Lutz in 1923 [50].



thalmoplegia (INO) which consists of adduction deficit on the side of MLF lesion during lateral gaze toward the opposite site with dissociated nystagmus of the abducting eye. The syndrome was first reported by Bielschowsky in 1902.

In 1923 Lutz described a variant of INO in which abduction of one eye is restricted (but preserved with reflex manoeuvres) on lateral gaze with a dissociated nystagmus in the adducting eye (fig. 9) [50, 51]. Convergence is typically preserved in posterior INO. Rostral pontine or mesencephalic lesions are typically found [52]. Abduction paresis is attributed to impaired inhibition of the tonic resting activity of the antagonistic medial rectus muscle [53].

Anton Renggli Lutz (1883–1948) was an ophthalmologist who was trained in Zurich (1908) and emigrated to Cuba, where he made this seminal neuro-ophthalmological observation.

Morel's syndrome
(Morgagni-Stewart-Morel's syndrome)

The syndrome, first reported autopsically by Morgagni and Santorini in 1719, consists of the triad (1) hyperostosis frontalis interna, (2) obesity and (3) virilism/hirsutism. Neurological symptoms are not uncommon and include migrainous headaches, cranial nerve palsies (hyposmia, vertigo, trigeminal/facial palsy, etc.), seizures and cognitive decline. Morel reported the first living case of the syndrome in 1930. The aetiology of this rare disorder is unknown but includes genetic factors (as it has been observed in identical twins) [54].

Ferdinand Morel (1888–1957), born in Moutier, first studied theology and philosophy. He served as chair of psychiatry in Geneva and was successor of Charles Ladame at Bel-Air Hospital, where he introduced new methods of investigations (endocrinology, biochemistry, EEG). He was among the few psychiatrists of his time to oppose psychosurgery, which had been started worldwide in Neuchâtel in 1891 by Gottlieb Burckhardt [55].

Prader-Willi's syndrome
(Prader-Labhart-Willi's syndrome)

In 1956 Prader together with Labhart and Willi first described a syndrome characterised at birth by poor muscle tone (floppy child) and poor sucking, later by short stature, adipositas, hypogonadism and mental retardation [56, 57].

Andrea Prader (1919–2001), born in Samedan, succeeded Fanconi as chair of the University Chil-

dren's Hospital in Zurich (1962–1986) and served as president of the European Society for Paediatric Endocrinology.

Roussy-Lévy's syndrome
(hereditary areflexic dystasia)

In 1926 Roussy described with Gabrielle Lévy a large family presenting with gait ataxia, pes cavus, areflexia, distal muscle atrophy, postural tremor and minor sensory loss. Neuropathological, electrophysiological and genetic testing indicate that the syndrome represents a phenotypic variant of the Charcot-Marie-Tooth disease 1B subtype associated with a duplication on chromosome 17 [58].

Vieusseux-Wallenberg's syndrome

The first description of Wallenberg's syndrome dates back to Gaspard Vieusseux (1746–1814) from Geneva, who in 1808–1810 gave a description of his own disease at the medical and surgical society of Geneva first and later in London, well before the description made in 1895 by Adolf Wallenberg (1862–1949) [59]. Vieusseux also gave one of the first descriptions of epidemic cerebrospinal meningitis.

Von Monakow's syndrome
(syndrome of the anterior choroidal artery)

This eponym refers to the syndrome of anterior choroidal artery, which consists of hemiparesis, hemianaesthesia and homonymous hemianopia. This clinical triad is often incomplete and infarctions may present with a lacunar syndrome (pure motor or pure sensory deficits). Cortical symptoms/signs may also be present.

The syndrome was first recognised by von Monakow (who cited it in his book "Gehirnpathologie" [20]) and later confirmed by Kolisko in 1891 (who referred to von Monakow) and Foix et al. in 1925 [60, 61].

Zellweger-Bower's syndrome
(cerebro-hepato-renal syndrome)

This eponym, first reported in 1964, refers to an autosomal recessive syndrome characterised by microgyria, abnormal skull, mental and growth retardation, craniofacial malformations, seizures, hypospadias, glaucoma, cataracts, cysts of the kidney and hepatomegaly. Cardiac complications in-

clude patent ductus arteriosus and septal defects. The characteristic lesion is a lack or absence of peroxisomes in many tissues. Death occurs within a few weeks or months of life.

Hans Ulrich Zellweger (1909–1990) was born in Lugano and studied in Zurich, Hamburg, Berlin and Rome. During the years 1937–1939 he worked with Albert Schweitzer in Equatorial Africa. From 1939 on he worked with Fanconi at the Children's Hospital in Zurich. In 1951 he became professor of paediatrics at the American University in Beirut (Lebanon). In 1959 he immigrated to the United States of America to take up a similar position at the University of Iowa.

Acknowledgements: Julien Bogousslavsky, Eugen Boltschauser, Hansruedi Isler, Caroline Jagella, Marco Mumenthaler and Michel Magistris made helpful comments to this article.

References

- 1 Bassetti C. Die Gründer der klinischen Neurologie. Schweiz Rundsch Med Prax. 1994;16:470–6.
- 2 Barrows HS. Neurological eponyms. Arch Neurol. 1960;3:113–9.
- 3 Bruyn GW, Goody G. Horner's syndrome. In: Koehler PJ, Bruyn GW, Pearce JMS, editors. Neurological Eponyms. New York: Oxford University Press; 2000. p. 227–33.
- 4 Wartenberg R. The Examination of Reflexes. Chicago: The Year Book Publishers; 1946.
- 5 Hachinski V. The upgoing thumb sign. Archiv Neurol. 1992;49:346.
- 6 Koehler PJ, Bruyn GW, Pearce JMS. Neurological Eponyms. New York: Oxford University Press; 2000.
- 7 Akert K. Vierhundert Jahre Hirnforschung in der Schweiz. Zürich: Naturforschende Gesellschaft in Zürich; 1997.
- 8 Bing R. Ein neues Zeichen organisch bedingter Spastizität. Correspondenz-Blatt für Schweizer Aerzte. 1918;48:465–7.
- 9 Bing R. Kompendium der topischen Gehirn- und Rückenmarksdagnostik. Basel: Benno Schwabe; 1953.
- 10 Minkowski M. 50 Jahre Schweizerische Neurologische Gesellschaft. Schweiz Arch Neurol Psychiatr. 1958;82:4–181.
- 11 van Gijn J. The Babinski sign – a centenary –. Utrecht: Universiteit Utrecht; 1996.
- 12 Lüthy F. Der Flaschentest zur Erkennung der Medianuslähmung. Schweiz Med Wochenschr. 1962;92:1573–5.
- 13 Magistris MR, Kohler A. Contraction response to muscle percussion is increased in peripheral conduction block. Neurology. 1996;47:1243–6.
- 14 von Monakow C. Ueber den äusseren und inneren Fussrandreflex. Neurologisches Zentralblatt. 1909;28:671–2.
- 15 DeJong RN. The Neurologic Examination. New York: Hoeber, P.B.; 1950.
- 16 Minkowski M. Constantin von Monakow 1853–1930. Schweiz Arch Neurol Psychiatr. 1931;27:1–63.
- 17 Landolt H. Some clinical electroencephalographic correlations in epileptic psychosis. Electroencephalogr Clin Neurophysiol. 1953;5:121–30.

- 18 Schmitz B. Forced normalization: history of a concept. In: Trimble MR, Schmitz B, editors. *Forced Normalization and Alternative Psychoses of Epilepsy*. Petersfield, UK, and Bristol, PA, USA: Wrighton Biomedical Publishing LTD; 1998.
- 19 Karbowski K. Rudimentäre psychomotorische Anfälle und ihre Differentialdiagnose. *Schweiz Rundsch Med Prax*. 1990;24:772–6.
- 20 von Monakow C. *Gehirnpathologie*. Zweite, gänzlich umgearbeitete und vermehrte Auflage. Wien: Hödler, A.; 1905.
- 21 von Monakow C. Die Lokalisation im Grosshirn und der Abbau der Funktion durch kortikale Herde. Wiesbaden: Bergmann, J.F.; 1914.
- 22 Koehler PJ, Jagella C, Isler H. Zur Rezeption von Monakows Werk. *Schweiz Arch Neurol Psychiatr*. 1995;146:31–9.
- 23 Andrews RJ. Transhemispheric diaschisis. A review and comment. *Stroke*. 1991;22:943–9.
- 24 Finger S, Koehler PJ, Jagella C. The Monakow concept of diaschisis: origins and perspectives. *Arch Neurol*. 2004;61:283–8.
- 25 Heyck H. On Bing's headache syndrome. *Dtsch Med Wochenschr*. 1962;87:1942–7.
- 26 Pearce JMS. Gerardi van Swieten: descriptions of episodic cluster headache. *J Neurol Neurosurg Psychiatr*. 2007;78:1248–9.
- 27 Boes CJ, Capobianco DJ, Matharu MS, Goadsby PJ. Wilfred Harris' early description of cluster headache. *Cephalalgia*. 2002;22:320–6.
- 28 Edmeads J. The cervical spine and headache. *Neurology*. 1988;38:1874–8.
- 29 Binswanger O. Die Abgrenzung der allgemeinen progressiven Paralyse. *Klin Wochenschr*. 1894;31:1103–5, 1137–9, 1180–6.
- 30 Pearce JMS. Binswanger's "encephalitis subcortical chronica progressiva". *J Neurol Neurosurg Psychiatr*. 1997;63:308.
- 31 Loeb C. Binswanger's disease is not a single entity. *Neurol Sci*. 2000;21:343–8.
- 32 Teunisse RJ, Cruysberg JR, Hoefnagels WH, Verbek AL, Zitman FG. Visual hallucinations in psychologically normal people: Charles Bonnet's syndrome. *Lancet*. 1996;347:794–7.
- 33 de Morsier G. Les hallucinations. *Rev Otoneuroophthalmol*. 1938;16:244–352.
- 34 Dejerine J, Roussy G. Le syndrome thalamique. *Revue Neurologique*. 1906;12:521–32.
- 35 Cambier J. Le syndrome de Dejerine-Roussy. *Revue Neurologique*. 1982;138:979–88.
- 36 De Smet Y. Le syndrome thalamique de Dejerine-Roussy. *Revue Neurologique*. 1986;142:259–66.
- 37 Bassetti CL, Jagella EC. Joseph Jules Dejerine (1849–1917). *J Neurol*. 2006;253:823–4.
- 38 Jagella EC, Krestel H, Bassetti CL. Augusta Dejerine-Klumpke (1859–1927). *J Neurol*. In press 2008.
- 39 Minkowski M. Louis Rudolphe Brun (1885–1969). *Schweiz Arch Neurol Psychiatr*. 1969;106:330–4.
- 40 de Morsier G. Etudes sur les dysraphies crânio-encephaliques. I. Agénésie des lobes olfactifs et des commissures calleuse et antérieure. *Schweiz Arch Neurol Psychiatr*. 1954;74:309–61.
- 41 Fanconi G, Turler U. Congenital cerebellar atrophy with supranuclear disturbance of ocular motility. *Helv Paediatr Acta*. 1951;6:475–83.
- 42 Glanzmann E, Saland S. Seltene postdiphtherische Lähmungen. *Schweiz Med Wochenschr*. 1935;16:2–5.
- 43 Horner JF. Ueber eine Form von Ptosis. *Klin Monatsbl Augenheilkd*. 1869;7:193–8.
- 44 Ciba A, Basel. *Schweizer Aerzte als Forscher, Entdecker und Erfinder*. Basel: Birkhäuser; 1945.
- 45 Poretti A, Boltshauser E, Loenneker T, Valente EM, Brancati F, Il'yasov K, et al. Diffusion tensor imaging in Joubert syndrome. *Am J Neuroradiol*. 2007;28:1929–33.
- 46 Boltshauser E, Isler W. Joubert syndrome: episodic hyperpnea, abnormal eye movements, retardation and ataxia, associated with dysplasia of the cerebellar vermis. *Neuropediatrics*. 1977;8:57–66.
- 47 Kaeser HE. Scapulo-peroneal muscular atrophy. *Brain*. 1965;88:407–18.
- 48 Kaeser HE. Die familiäre skapulo-peroneale Muskelatrophie. *Dtsch Z Nervenheilkd*. 1964;186:379–94.
- 49 Walter MC, Reilich P, Huebner A, Fischer D, Schröder R, Vorgerd M, et al. Scapulo-peroneal syndrome type Kaeser and a wide phenotypic spectrum of adult-onset, dominant myopathies are associated with the desmin mutation R350P. *Brain*. 2007;130:1485–96.
- 50 Lutz A. Ueber die Bahnen der Blickwendung und deren Dissoziierung. *Klin Monatsbl Augenheilkd*. 1923;70:213.
- 51 Topilow HW. Posterior internuclear ophthalmoplegia of Lutz. *Ann Ophthalmol*. 1981;13:221–5.
- 52 Thömke F, Hopf HC, Krämer G. Internuclear ophthalmoplegia of abduction: clinical and electrophysiological data on the existence of an abduction paresis of prenuclear origin. *J Neurol Neurosurg Psychiatr*. 1992;55:105–11.
- 53 Brazis PW, Masdeu JC, Biller J. *Localization in Clinical Neurology*. Philadelphia: Lippincott, Williams and Wilkins; 2007.
- 54 Koller MF, Papassotiropoulos A, Henke K, Behrends B, Noda S, Kratzer A, et al. Evidence of a genetic basis of Morgagni-Stewart-Morel syndrome: a case report of identical twins. *Neurodegener Dis*. 2005;2:56–60.
- 55 Montmollin D. Dr. Ferdinand Morel, Geneva (1888–1957). *Schweiz Arch Neurol Neurochir Psychiatr*. 1959;83:342–4.
- 56 Prader A, Labhart A, Willi H. Ein Syndrom von Adipositas, Kleinwuchs, Kryptorchismus und Oligophrenie nach myotonieartigem Zustand im Neugeborenenalter. *Schweiz Med Wochenschr*. 1956;86:1260–1.
- 57 Couper RTL, Couper JJ. Prader-Willi syndrome. *Lancet*. 2000;356:673–5.
- 58 Planté-Bordeneuve V, Guiochon-Mantel A, Lacroix C, Lapresle J, Said G. The Roussy-Lévy family: from the original description to the gene. *Ann Neurol*. 1999;46:770–3.
- 59 Romano J, Merritt HH. The singular affection of Gaspard Vieusseux. *Bulletin of History of Medicine*. 1941;9:72–9.
- 60 Kolisko A. Ueber die Beziehungen der Arteria choroidea anterior zum hinteren Schenkel der inneren Kapsel des Gehirns. Wien: Haelder, A.; 1891.
- 61 Foix C, Chavany JA, Hillemand P, Schiff-Wertheimer S. Oblitération de l'artère choroïdienne antérieure. Ramollissement cérébral: hémiparésie, hémianesthésie, hémianopsie. *Bulletin of the Society of Ophthalmology*. 1925;37:221–3.