

Neurologist-in-training

The aim of this section is to prepare the neurologist-in-training for the FMH examination, to confront her or him with specific problems of

everyday neurological practice and to give him or her updates on recent controversies in clinical neurology.

Contributions and correspondence to Hans H. Jung who is responsible for this section:

PD Dr. med. Hans H. Jung, Department of Neurology, University Hospital Zurich, Frauenklinikstrasse 26, CH-8091 Zurich, hans.jung@usz.ch

Case vignette

The 62-year-old right-handed woman presented at our department because of increasing vertigo and disabling walking difficulties. Six years ago, she was suffering from attacks of vertigo, vomiting and walking difficulties, which lasted about two weeks. At this time, the patient was diagnosed with Menière's disease. One and a half years ago, she had again attacks with similar symptoms. Thereafter, walking difficulties gradually increased, in particular in darkness. In

addition, she noticed that she could not visually fix upon objects while moving her head. Nobody else in her family had ever had similar problems. The neurological examination revealed a cerebellar syndrome with cerebellar ocular motor signs, severe gait ataxia, evidence for a right vestibular neuropathy and a slight sensory polyneuropathy. The resident of the ward diagnosed a right peripheral vestibulopathy and suspected an additional progressive spinocerebellar ataxia.

Question 1

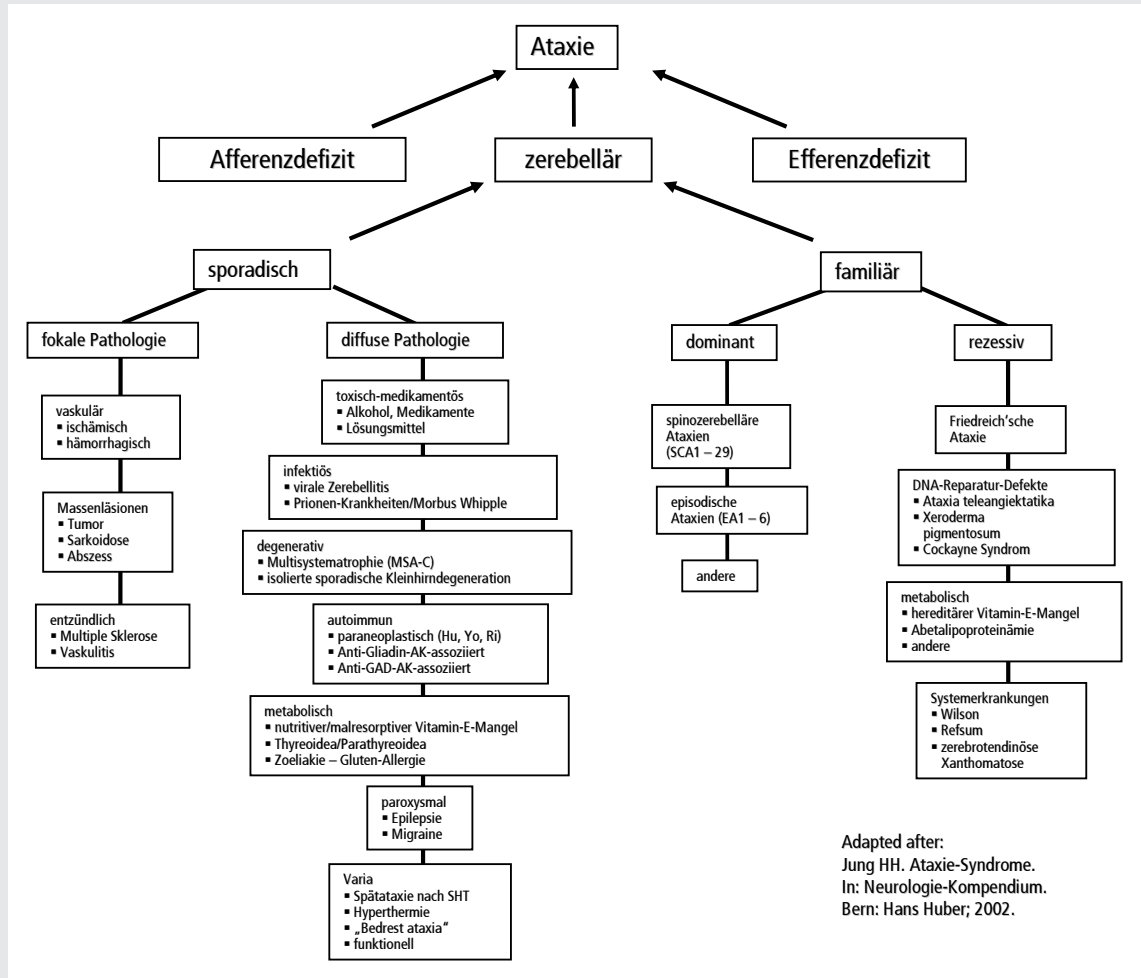
Which are typical cerebellar ocular motor signs?

Question 2

What is the most appropriate bedside test for the detection of a peripheral vestibulopathy?

Question 3

The patient's history and clinical findings indicate an acute peripheral vestibulopathy on the right side, probably due to a vestibular neuritis. In addition, there is evidence of a chronic progressive spinocerebellar syndrome. Concerning the latter syndrome, which differential diagnosis is indispensable and which laboratory tests should be performed?

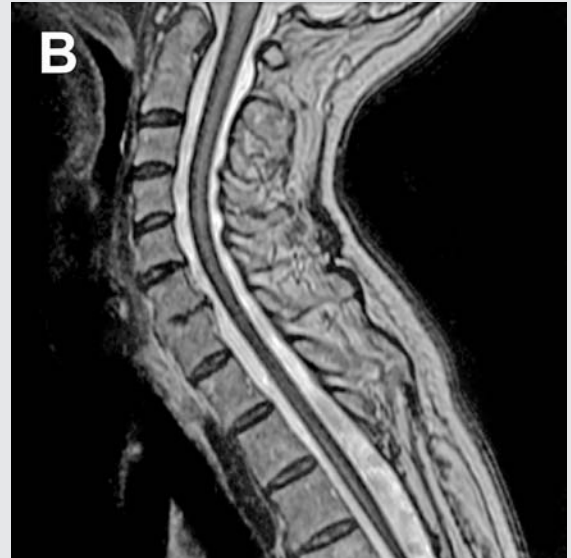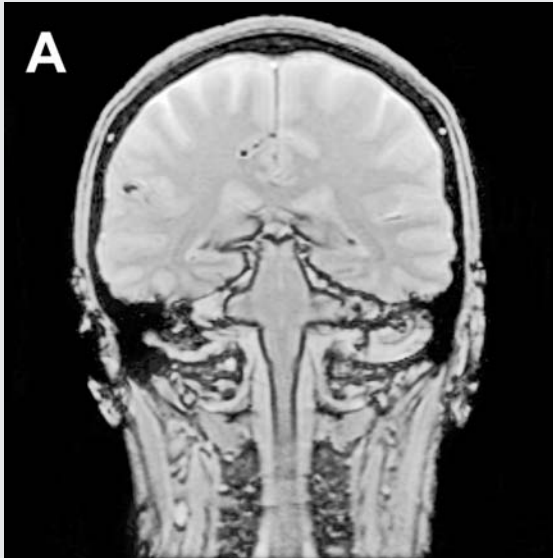


(For correct answers, see page 270)

Additional examinations

All serum values in this patient were normal. However, CSF examination revealed xanthochromia and 14 000 erythrocytes per micro-litre CSF. Magnetic resonance imaging (MRI) showed a moderate cerebellar atrophy and

an extended superficial haemosiderosis of the neuroaxis (fig. A and B). Cerebral and spinal digital subtraction angiography revealed no bleeding source.



Diagnosis

Idiopathic superficial haemosiderosis with a progressive spinocerebellar syndrome and right peripheral vestibulopathy.

Epicrisis

Treatment with recurrent blood tapping of 400 ml was initiated every one to three months adapted to the haematocrit. Under this treatment the patient's condition stabilised for several months but there was no clear improvement of the cerebellar syndrome.

Take-home message

→ Idiopathic superficial haemosiderosis is a rare cause of a progressive cerebellar syndrome.

→ In spinocerebellar syndromes a structured work-up is crucial to detect potentially treatable causes.

→ Hereditary spinocerebellar syndromes may be present in the absence of a positive family history.

Acknowledgments: Many thanks to the colleagues who contributed to the diagnosis and care of the patient, namely to Ch. Baumann, M. Bischof, S. Hyrenbach, S. Marti, B. Schuknecht, D. Straumann, A. Valavanis and V. Zumsteg.

Suggested reading

Fogel L, Perlman S. Clinical features and molecular genetics of autosomal recessive cerebellar ataxias. *Lancet Neurol.* 2007;6:245–57.

Halmagyi GM, Curthoys IS. A clinical sign of canal paresis. *Arch Neurol.* 1988;45:737–9.

Jen JC, Graves TD, Hess EJ, Hanna MG, Griggs RC, Baloh RW. Primary episodic ataxias: diagnosis, pathogenesis and treatment. *Brain.* 2007;130:2484–93.

Jorns-Häderli M, Straumann D, Palla A. Accuracy of the bedside head impulse test in detecting vestibular hypofunction. *J Neurol Neurosurg Psychiatry.* 2007;78:1113–8.

Jung HH, Vuadens P, Hess K. Ataxie-Syndrome. In: Hess K, Steck A, editors. *Neurologie-Kompendium.* Bern: Hans Huber; 2002. S. 80–96.

Kumar N. Superficial siderosis: associations and therapeutic implications. *Arch Neurol.* 2007;64:491–6.

Soong BW, Paulson HL. Spinocerebellar ataxias: an update. *Curr Opin Neurol.* 2007;20:438–46.

Answer 1

- Gaze-evoked nystagmus with rebound nystagmus
- Deficient smooth pursuit eye movements
- Incomplete visual suppression of the vestibulo-ocular reflex
- Dysmetric saccades
- Downbeat nystagmus (not in this patient!)

Answer 2

The head impulse test, first described by *Halmagyi* and *Curthoys*, is the most appropriate test for the detection of a one-sided or bilateral peripheral vestibulopathy. For this test the examiner sits in front of the subject, who visually fixes the nose of the examiner. The examiner quickly turns the subject's head 5–15° to either side. If the peripheral vestibular function is normal, the subject's eyes will remain fixed upon the examiner's nose. In a peripheral vestibular deficit gaze cannot be stabilised when the head is quickly rotated in the direction of the affected ear. Consequently, after the head impulse the patient makes a correcting saccade to re-direct the gaze back to the nose of the examiner.

Answer 3

The distinction between sporadic and hereditary causes of a spinocerebellar syndrome is crucial to detect potentially treatable causes, as indicated in the flow chart. Laboratory examinations to be ordered include white and red blood count, thyroid stimulating hormone (TSH), cholesterol, lipoprotein electrophoresis, creatin kinase (CK), vitamin B₁₂ and E as well as antibodies directed against GAD, gliadin and Purkinje cells (ANNA, Hu, Yo, Ri). Examination of the cerebrospinal fluid (CSF) may reveal infectious causes. In cases with suspected Wilson's disease excretion of copper in the urine over 24 hours should be measured. In addition, a magnetic resonance imaging should be performed to detect structural alterations. The course of the disease over more than one and a half years is suspicious for a hereditary cause. Even in the absence of a positive family history, a hereditary spinocerebellar syndrome might be present. An autosomal recessive Friedreich's ataxia may have a late onset; in these cases frequently retained tendon reflexes are seen. In addition, autosomal dominant spinocerebellar ataxias (SCA) may be present without positive family history due to neomutations, reduced penetrance in the ancestors or incorrect paternity.