

Laparoscopy for relapsing paralytic ileus in multiple sclerosis: a video case report

Chiario Giacomo^{ab}, Fratila Corneliu^a, Martig Franz^c, Zecca Chiara^d, Gobbi Claudio^d

^a Neurocentre of Southern Switzerland, Civic Hospital of Lugano, Switzerland

^b Department of Biomedical and Neuromotor Sciences, University of Bologna, Italy

^c Department of Surgery, Civic Hospital of Lugano, Lugano, Switzerland

^d Faculty of Biomedical Sciences, Università della Svizzera Italiana, Lugano, Switzerland

Summary

Autonomic failure, especially of the gastrointestinal tract, has been detected in a wide range of multiple sclerosis patients with very variable frequencies. Acute manifestations of gastrointestinal dysfunction, however, are rarely reported. We describe an multiple sclerosis patient with a relapsing form of acute paralytic ileus in the context of acute autonomic failure requiring surgery.

Keywords: multiple sclerosis, autonomic failure, dysautonomia, autonomic nervous system, paralytic ileus, sub-obstructive ileus, enteric nervous system

Introduction

Autonomic failure (AF) has been previously described in patients with multiple sclerosis (MS) [1]. Prominent involvement of the cardiovascular, urinary and gastrointestinal branches of the autonomic nervous system (ANS) has been detected in a wide range of MS patients with very variable frequencies [2], either through dedicated questionnaires, or by means of laboratory autonomic function tests (AFT) [3].

Gastrointestinal dysfunction is particularly remarkable in MS, with both constipation and faecal incontinence being its most prevalent manifestations [4, 5]. In one questionnaire-based series of 218 patients with MS, 43% claimed to be constipated, 51% complained of faecal incontinence and 68% of any bowel dysfunction [6]. Patients with higher disability and longer duration of MS tend to have greater prevalence and severity of bowel symptoms [7].

Acute manifestations of gastrointestinal dysfunction, ranging from acute dysphagia to gastroparesis to acute paralytic ileus are, however, rarely reported (for references, see table 1). In this case report, we describe a patient with a stable MS presenting with a relapsing form of acute paralytic ileus requiring surgery.

Report of case

A 44-year-old woman with a 10-year history of clinically stable, relapsing-remitting MS characterised by mild functional disability (Expanded Disability Status Scale, EDSS

2.0 defined by relevant fatigue) and treated with interferon beta-1a 44 µg (Rebif[®]) for the last 5 years was admitted to the emergency department because of sudden abdominal pain, nausea and vomiting. She had last passed stools 2 days before and had no fever. Her medical history was otherwise unremarkable, she had no allergy history, her food habits had been stable and she had not travelled during the previous months. Clinical examination was remarkable for epigastric tenderness, with no signs of peritoneal irritation. Routine laboratory tests, including inflammatory indices, liver and biliary tract, kidney function, lactates and creatine phosphokinase were all normal. A detailed review of ANS symptoms by use of the Italian version of the Composite Autonomic Symptoms Scale-31 (COMPASS-31) [8] disclosed a selective involvement of the enteric nervous system in terms of constipation. Orthostatic intolerance, pupillomotor, vasomotor, secretomotor or bladder dysfunctions were absent. A simple supine versus standing blood pressure measurement excluded orthostatic hypotension or postural tachycardia. A thorough neurological examination did not show any other sign of AF.

Abdominal computed tomography (CT) showed signs of mechanical small bowel obstruction with a possible beak and faeces sign. As there were no clear signs of bowel wall injury or free fluid collection, conservative treatment was tried and interrupted after 24 hours, as the patient had faecal vomiting. An emergency diagnostic laparoscopy excluded mechanical obstruction, but showed an atonic bowel with complete absence of peristalsis (video 1). Liver and omental biopsies, as well as a cytological sample of intra-abdominal fluid, were collected and yielded negative results, thus excluding infectious, metabolic, ischaemic or pharmacological causes for the ileus. The clinical course was free from complications and the patient was discharged home 4 days later; no treatment was started.

After 5 days, she consulted our emergency department for recurrence of abdominal pain, nausea and vomiting, which had started 24 hours earlier. She had no fever, nor diarrhoea. Peristalsis was absent and no clinical signs of peritoneal irritation were found. Laboratory tests, abdominal radiography and CT scan were repeated, confirming the same diagnosis of paralytic ileus without mechanical ob-

Author contributions
Chiara Zecca and Claudio Gobbi contributed equally to this work.

Correspondence:
Dr Claudio Gobbi, MD,
Neurocentre of Southern
Switzerland, Via Tesserete,
48, CH-6900 Lugano, claudio.gobbi[at]eoc.ch

struction, which resolved after treatment with amidotrizoid acid and neostigmine.

Spinal 3T-magnetic resonance imaging (MRI) disclosed a stable lesion load compared to the year before, with a non-enhancing lesion anteriorly in the lower medulla, as well as multiple non-enhancing cervical and dorsal demyelinating lesions (at C1-2-3-4 and T8-9 levels) (fig. 1). Imaging of the lumbosacral spine did not show any pathological finding. The patient was discharged 4 days later. At a 1-year follow-up, the patient is stable and still taking interferon beta-1a. No new relapses took place.

Discussion

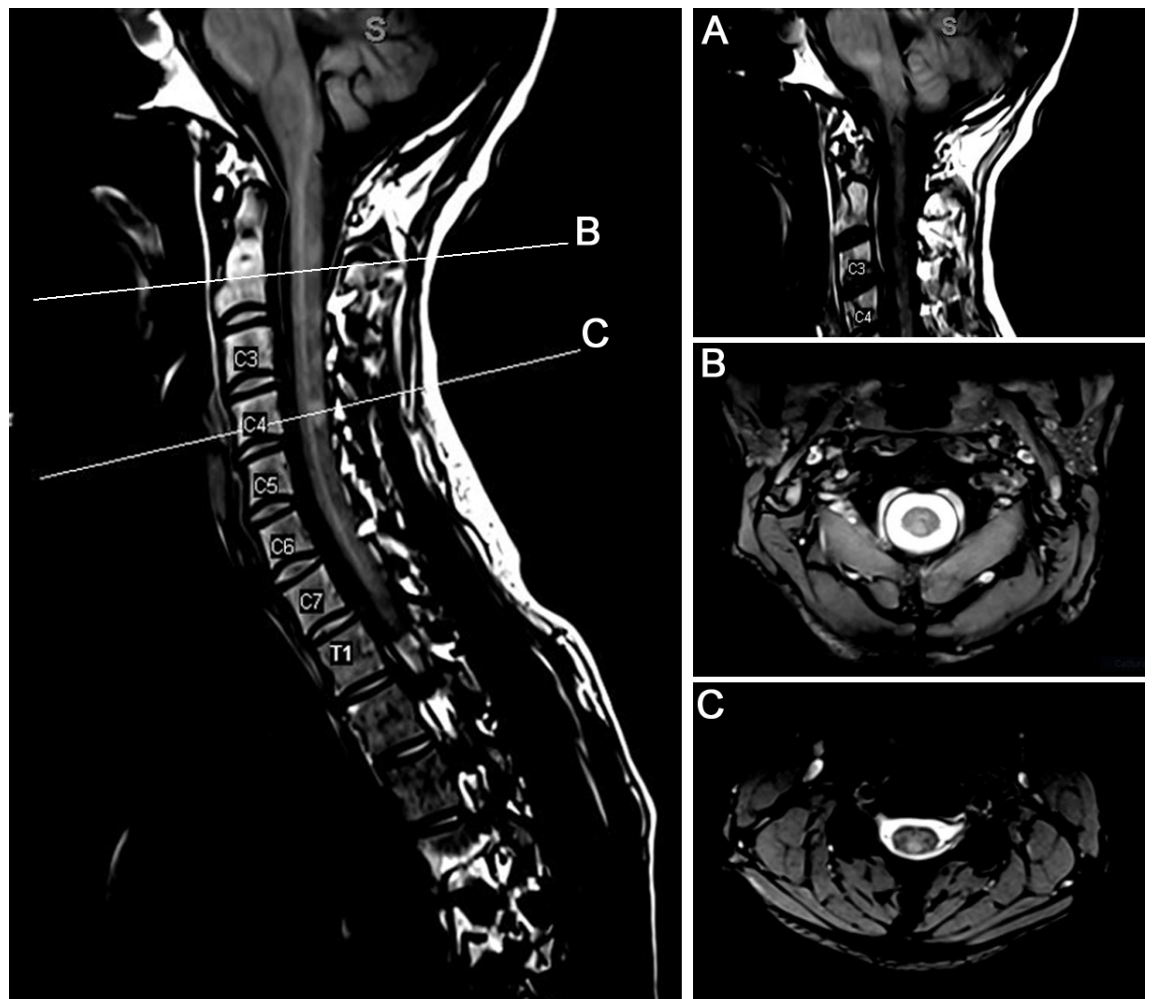
This case adds up to a growing number of reported cases of acute paralytic ileus occurring in MS patients (table 1). Historically, it has always been postulated that AF in MS patients is probably due to plaques distributed throughout the brainstem and spinal cord affecting anatomically widespread autonomic regulatory areas and their connections [1, 11, 15]. According to this viewpoint, it is also believed that the level of AF correlates both to spinal involvement and to MS disease severity [16–18]. Our patient presented multiple chronic and newly developed spinal lesions and her medical history was remarkable for dysautonomic symptoms, mostly involving the gastrointestinal system.

Given that infectious, compressive or structural causes for the ileus were excluded, we postulated that a relationship between a relapse of MS and the paralytic ileus is the most plausible explanation (table 2 for a selected differential diagnosis of ileus and mechanical obstruction).

Interestingly, it has been recently proposed that demyelination in MS does not occur only within the central but also in the peripheral nervous system. Early neuropathological reports described segmental demyelination, hypertrophic neuropathy and a reduction in myelin thickness in a few MS patients [19, 20]. A proof-of-concept study visualised and quantified peripheral nerve lesions in MS *in vivo* by means of high-resolution MRI studies [21]. These more recent findings offer grounds for speculation; indeed, in contrast to some of the previous records [9], in our case, none of the new spinal lesions showed contrast enhancement on MRI. It could be argued that more peripheral lesions, invisible to routine neuroimaging, might have played a role in precipitating the two episodes of paralytic ileus by unbalancing a pre-existing precarious equilibrium within the increased spinal lesion load.

Once all other causes of paralytic ileus have been ruled out or treated [22], neurologists should keep in mind that MS may cause acute and severe impairment of any part of the ANS, particularly in those patients with a previous history

Figure 1: T2-weighted 3-tesla MRI sequences showing non-enhancing lesions in the (A) anterior bulbo-medullary junction, (B) anterior portion of the medulla at C2 and (C) C4 levels. Smaller lesions are scattered throughout the cervical spine.



of dysautonomia and even in the absence of new contrast-enhanced spinal lesions.

Supplementary material:

Video on <https://sanp.ch/en/online-only-content/post/laparoscopy-for-relapsing-paralytic-ileus-in-multiple-sclerosis-a-video-case-report/>

Funding / potential competing interests

No financial support and no other potential conflict of interest relevant to this article was reported.

References

- McDougall AJ, McLeod JG. Autonomic nervous system function in multiple sclerosis. *J Neurol Sci.* 2003;215(1-2):79–85. [http://dx.doi.org/10.1016/S0022-510X\(03\)00205-3](http://dx.doi.org/10.1016/S0022-510X(03)00205-3). PubMed.
- Haensch CA, Jörg J. Autonomic dysfunction in multiple sclerosis. *J Neurol.* 2006;253(S1, Suppl 1):13–9. <http://dx.doi.org/10.1007/s00415-006-1102-2>. PubMed.
- Racosta JM, Sposato LA, Morrow SA, Cipriano L, Kimpinski K, Kremenchutzky M. Cardiovascular autonomic dysfunction in multiple sclerosis: a meta-analysis. *Mult Scler Relat Disord.* 2015;4(2):104–11. <http://dx.doi.org/10.1016/j.msard.2015.02.002>. PubMed.
- Levinthal DJ, Rahman A, Nusrat S, O'Leary M, Heyman R, Bielefeldt K. Adding to the burden: gastrointestinal symptoms and syndromes in multiple sclerosis. *Mult Scler Int.* 2013;2013. <http://dx.doi.org/10.1155/2013/319201>. PubMed.
- Wiesel PH, Norton C, Glickman S, Kamm MA. Pathophysiology and management of bowel dysfunction in multiple sclerosis. *Eur J Gastroenterol Hepatol.* 2001;13(4):441–8. <http://dx.doi.org/10.1097/00042737-200104000-00025>. PubMed.
- Hinds JP, Eidelman BH, Wald A. Prevalence of bowel dysfunction in multiple sclerosis. A population survey. *Gastroenterology.* 1990;98(6):1538–42. [http://dx.doi.org/10.1016/0016-5085\(90\)91087-M](http://dx.doi.org/10.1016/0016-5085(90)91087-M). PubMed.
- Nortvedt MW, Riise T, Frugård J, Mohn J, Bakke A, Skår AB, et al. Prevalence of bladder, bowel and sexual problems among multiple sclerosis patients two to five years after diagnosis. *Mult Scler.* 2007;13(1):106–12. <http://dx.doi.org/10.1177/1352458506071210>. PubMed.
- Pierangeli G, Turrini A, Giannini G, Del Sorbo F, Calandra-Buonaura G, Guaraldi P, et al. Translation and linguistic validation of the Composite Autonomic Symptom Score COMPASS 31. *Neurol Sci.* 2015;36(10):1897–902. <http://dx.doi.org/10.1007/s10072-015-2278-y>. PubMed.
- Nomura S, Shimakawa S, Kashiwagi M, Tanabe T, Fukui M, Tamai H. Acute abdominal pain as the only symptom of a thoracic demyelinating lesion in multiple sclerosis. *Brain Dev.* 2015;37(10):983–7. <http://dx.doi.org/10.1016/j.braindev.2015.03.006>. PubMed.
- Ielpo B, Venditti D, Manfredi P, Balassone V, Petrella G. Intestinal pseudo-obstruction in patient affected by multiple sclerosis: case report. *Colorectal Dis.* 2010;12(7 Online). PubMed.
- Lane SW, Pender MP. Intestinal pseudo-obstruction complicating multiple sclerosis. *Intern Med J.* 2005;35(3):191–2. <http://dx.doi.org/10.1111/j.1445-5994.2004.00753.x>. PubMed.
- Feldman S. [Paralytic ileus complicating multiple sclerosis]. *Harefuah.* 1977;92(5):203–5. [Article in Hebrew]. PubMed.
- Williams HT, Turner DT. Acute myelitis presenting as spastic colonic ileus. *Br J Surg.* 1972;59(11):918. <http://dx.doi.org/10.1002/bjs.1800591117>. PubMed.
- Ito T, Sakakibara R, Sakakibara Y, Mori M, Hattori T. Medulla and Gut. *Intern Med.* 2004;43(11):1091
- Vita G, Fazio MC, Milone S, Blandino A, Salvi L, Messina C. Cardiovascular autonomic dysfunction in multiple sclerosis is likely related to brainstem lesions. *J Neurol Sci.* 1993;120(1):82–6. [http://dx.doi.org/10.1016/0022-510X\(93\)90029-X](http://dx.doi.org/10.1016/0022-510X(93)90029-X). PubMed.
- Gunal DI, Afsar N, Tanridag T, Aktan S. Autonomic dysfunction in multiple sclerosis: correlation with disease-related parameters. *Eur Neurol.* 2002;48(1):1–5. <http://dx.doi.org/10.1159/000064949>. PubMed.
- Saari A, Tolonen U, Pääkkö E, Suominen K, Pyhtinen J, Sotaniemi K, et al. Cardiovascular autonomic dysfunction correlates with brain MRI lesion load in MS. *Clin Neurophysiol.* 2004;115(6):1473–8. <http://dx.doi.org/10.1016/j.clinph.2004.01.012>. PubMed.
- Flachenecker P, Reiners K, Krauser M, Wolf A, Toyka KV. Autonomic dysfunction in multiple sclerosis is related to disease activity and progression of disability. *Mult Scler.* 2001;7(5):327–34. <http://dx.doi.org/10.1177/135245850100700509>. PubMed.
- Hasson J, Terry RD, Zimmerman HM. Peripheral neuropathy in multiple sclerosis. *Neurology.* 1958;8(7):503–10. <http://dx.doi.org/10.1212/WNL.8.7.503>. PubMed.
- Pollock M, Calder C, Allpress S. Peripheral nerve abnormality in multiple sclerosis. *Ann Neurol.* 1977;2(1):41–8. <http://dx.doi.org/10.1002/ana.410020107>. PubMed.
- Jende JME, Hauck GH, Diem R, Weiler M, Heiland S, Wildemann B, et al. Peripheral nerve involvement in multiple sclerosis: Demonstration by magnetic resonance neurography. *Ann Neurol.* 2017;82(5):676–85. <http://dx.doi.org/10.1002/ana.25068>. PubMed.
- Harrison ME, Anderson MA, Appaleni V, Banerjee S, Ben-Menachem T, Cash BD, et al.; ASGE Standards of Practice Committee. The role of endoscopy in the management of patients with known and sus-

Table 1: Previous case reports describing acute lower gastrointestinal involvement related to MS.

Article	Clinical description	Diagnosis	MRI findings
Nomura et al. 2015 [9]	7-year-old child with acute abdominal pain and paralytic ileus	MS-RR	Lesion on T4-T12
Ielpo et al. 2010 [10]	64-year-old woman, intestinal pseudo-obstruction	MS	
Lane et al. 2005 [11]	49-year-old man, intestinal pseudo-obstruction	MS-PP	
	49-year-old woman, gastroparesis, oesophageal dysmotility, faecal incontinence, intestinal pseudo-obstruction, megacolon	MS	
	35-year-old woman, severe vomiting, intestinal pseudo-obstruction	MS-SP	
Feldman et al. 1977 [12]	Paralytic ileus		
Williams et al. 1972 [13]	Pseudo-obstruction	Acute myelitis	
Ito et al. 2004 [14]	19-year-old girl, pseudo-obstruction	MS	Left medullary basis, vagal nerve root

MS = multiple sclerosis; MS-RR = multiple sclerosis, relapsing-remitting; MS-PP = multiple sclerosis, primary progressive; MS-SP = multiple sclerosis, secondary progressive

Table 2: A selected differential diagnosis of possible causes of paralytic ileus and mechanical causes of bowel obstruction.

Causes of paralytic ileus may include:	Mechanical causes of bowel obstruction may include:
<ul style="list-style-type: none"> Bacterial or viral gastroenteritis Chemical, electrolyte, or mineral imbalances Abdominal surgery Decreased blood supply to the intestines Abdominal infections (e.g. appendicitis) Kidney or lung disease Drugs, especially narcotics 	<ul style="list-style-type: none"> Adhesions or scar tissue that form after surgery Foreign bodies Gallstones (rare) Hernias Impacted stool Intussusception Tumours blocking the intestines Volvulus

pected colonic obstruction and pseudo-obstruction. *Gastrointest Endosc.* 2010;71(4):669–79 . <http://dx.doi.org/10.1016/j.gie.2009.11.027>. PubMed.